

# Aging a Deer by Examining Its Jawbone

Successful deer management involves keeping accurate harvest records and manipulating several deer population parameters, including the sex and age ratio of the deer herd. Managing the age structure of the buck segment of the population is considered one of the most important factors for improving the quality of the deer herd within a particular area.

## Aging techniques

The age of a deer can be estimated from the dental characteristics of the lower jaw. The two techniques used to determine the age of deer from the jawbone are *tooth replacement and wear* and *cementum annuli*.

### Tooth replacement and wear technique

The majority of deer harvested are aged using the tooth replacement and wear technique. This technique simply requires determining which teeth are present in the jawbone and how worn those teeth are. Figure 1 depicts the general anatomy of the molars in a deer's lower jaw.

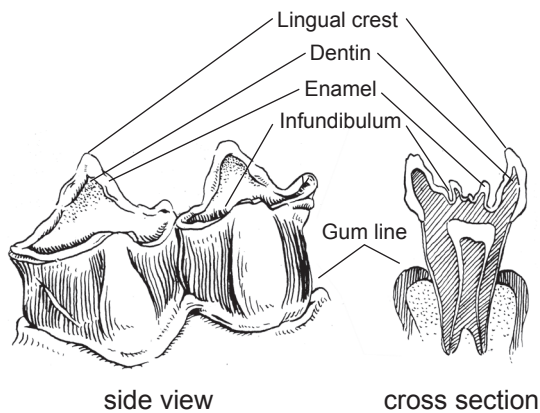


Figure 1. Anatomy of a deer molar.

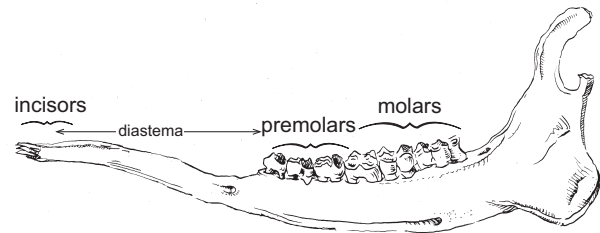


Figure 2. The deer jaw consists of incisors in the front, premolars and molars in the back, and a wide gap called the diastema in between.

Figure 2 depicts the jawbone of a healthy adult white-tailed deer. The incisors are the teeth in the front of a deer's mouth. Premolars and molars are located along the side of the jaw, separated from the incisors by a wide gap called the diastema. Deer do not have any top front teeth but only a rough palate. As a result, vegetation bitten off by deer appears to have been torn off and has a rough edge, whereas vegetation snipped off by rabbits or groundhogs is clean and smooth.

Based on which teeth are present, deer can be placed into one of three general age classes: fawn, 1½ years old (sometimes referred to as “yearling”) and adult. Accurately aging a deer past 2½ years, however, requires a little more practice and experience. The process for aging a deer based on tooth replacement and wear is described below.

---

### Glossary of deer tooth terms

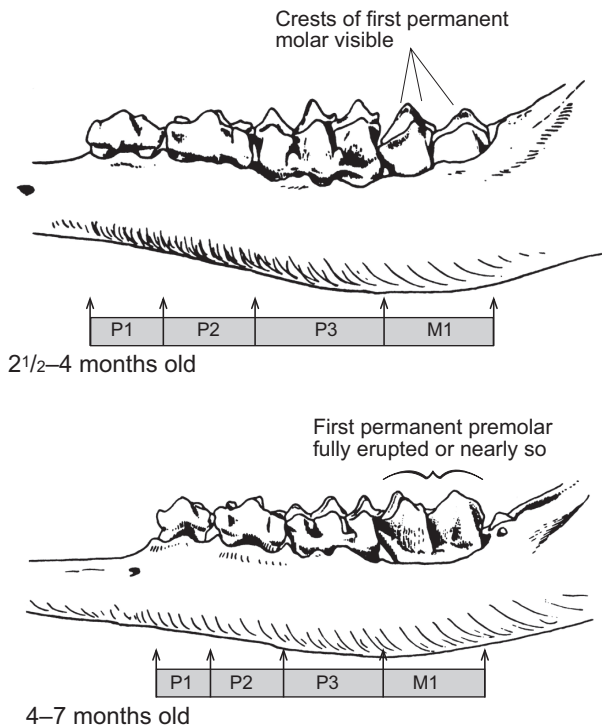
- cusps** The points or projections on the surface of a tooth.
  - dentin** The softer inner core of a tooth, much darker in color than the enamel.
  - enamel** The hard, white outer coat of a tooth.
  - gum line** Point to which flesh of the gum covers a tooth.
  - infundibulum** The funnel-shaped depression in the central crown of tooth between the crests; exterior surfaces will be stained dark.
  - lingual crests** Tooth ridges running from front to back adjacent to the tongue.
  - milk teeth** Temporary teeth in young animals, which are shed by 2 years of age.
  - molars** The large jaw teeth that grind food.
- 

This deer conservation guide is one in a series developed jointly by MU Extension and the Missouri Department of Conservation.

Written by  
**Robert A. Pierce II**, Fisheries and Wildlife State Specialist, School of Natural Resources  
**Jason Sumners**, Resource Scientist, Missouri Department of Conservation  
**Emily Flinn**, Resource Scientist, Missouri Department of Conservation

## Fawn

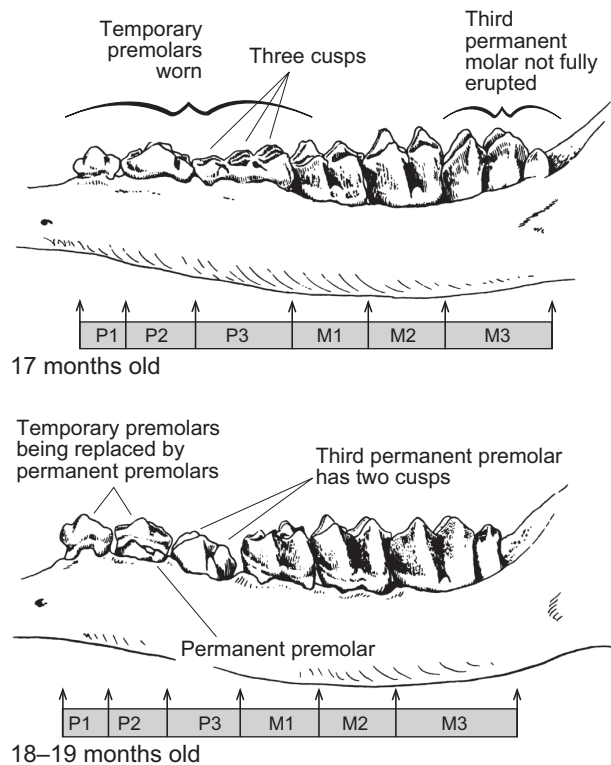
Fawns typically have only three or four fully erupted teeth along each side of the jaw. The first three are temporary premolars (P1, P2 and P3) and are called “milk teeth” because deer are born with these teeth in place. The third premolar (P3) has three cusps, which is important to note. If a fourth tooth is present, it is the first molar (M1). A deer with only three or four fully erupted teeth along the jaw is a fawn (Figure 3).



**Figure 3. A fawn has only three or four fully erupted teeth along each side of its jaw.**

## Yearling

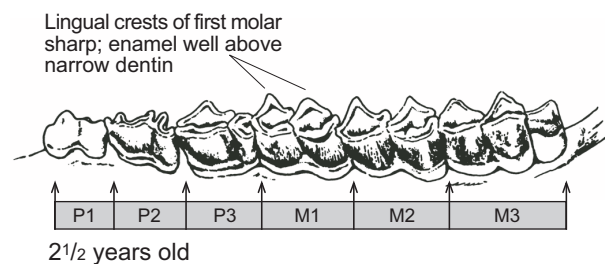
Yearlings generally have six fully erupted teeth along each side of the jaw. If the deer was born late or was killed early in the hunting season, the third molar (M3) may not be fully erupted. However, six teeth should be present along the jaw. Because the third premolar (P3) has not yet been replaced by a permanent P3, it still has three cusps. If the jawbone has six teeth along the side and P3 has three cusps, the deer is a yearling (1½ years old). However, the third premolar will be replaced at 18 or 19 months, which will be obvious as P3 will have 2 cusps, will be white and unstained, showing virtually no wear, and may not be fully erupted (Figure 4).



**Figure 4. Yearlings have six fully erupted teeth on each side.**

## Adult

Adult deer (2½ years and older) will have six fully erupted teeth along each side of the jaw: three permanent premolars and three permanent molars. Once again, note P3: It is now a permanent tooth and has only two cusps. In such cases, the deer is most likely an adult (Figure 5). However, as previously mentioned, a yearling could have a P3 with two cusps if it was an early-born fawn or was harvested late in the hunting season (into January).



**Figure 5. In an adult deer, P3 has only two crests.**

Aging of adult deer into older age classes requires evaluating the amount of wear on the teeth. Over time, teeth wear down, increasing the width of dentin (brown) exposed along each tooth's cusps. Specific age is estimated by comparing the width of dentin in relation to the width of enamel (white), while measuring overall wear (Figure 6). This deer-aging technique typically requires that the lower jawbone be extracted or the cheek cut away so that the teeth can be inspected closely.

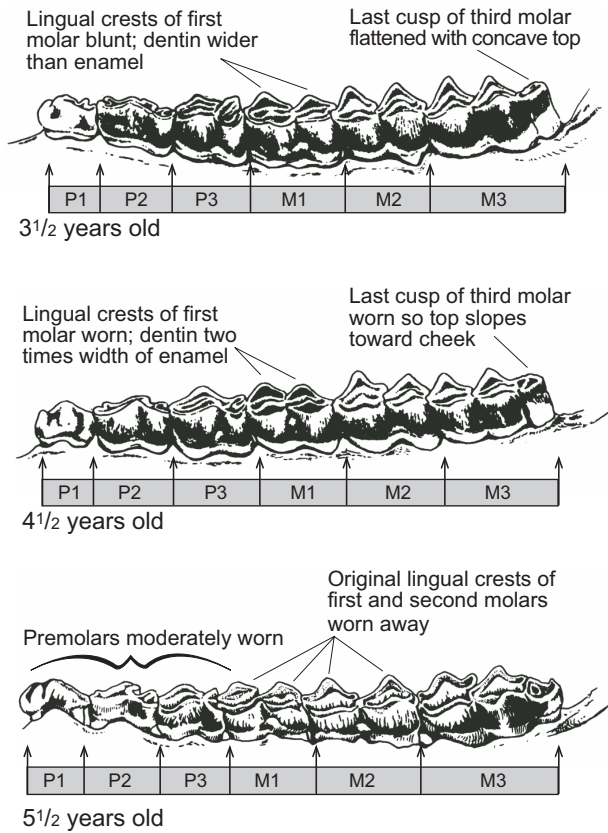


Figure 6. Accurately aging an adult deer past 2½ years requires close attention to tooth wear.

## Removing the jawbone for aging

Removing a deer's jawbone (mandible) for aging by tooth wear and replacement can be easily accomplished by using a pair of long-handled pruning shears and a jaw-extractor (Figure 7). Both of these tools can be purchased from various companies, including Forestry Suppliers at <http://www.forestry-suppliers.com>.



Figure 7. Pruning shears and a jaw extractor are two of the tools necessary to remove a deer's lower jaw for aging.

Follow these steps to remove the jaw:

1. Place the antlers or back of the head on the ground and insert the small end of the jaw extractor in the mouth, between the front teeth (incisors) and the first jaw teeth (premolars). Rotate the tool 90 degrees to open the mouth.
2. Insert the closed pruning shears through the jaw extractor. Open the shears and place the cutter bar behind the last jaw teeth (molars) on the outside of the jaw. Place the handles of the shears parallel to the roof of the animal's mouth and cut the bone and muscles.
3. Remove the shears and place the small end of the jaw extractor at the location where the lower jaw was cut. Pull the tool causing it to slide along the underside of the jaw, removing the muscles as it moves forward. The jaw will separate between the incisors and can be lifted out.
4. Lower jaws should be labeled with a corresponding deer number, date, weight, sex and number of points (Figure 8).



Figure 8. Label each deer jaw with identifying information about the deer to ensure harvest records are accurate.

## Cementum annuli technique

The cementum annuli technique is similar to aging a tree by counting growth rings and is the most reliable method for accurately estimating age. Each year as a deer ages, cementum is deposited on the external root surface of its teeth, resulting in a pattern of "rings." Counting these rings is relatively expensive because of the time and specialized laboratory equipment required to perform the analysis. Several commercial sources offer these services.

## Additional information

For more information on aging white-tailed deer by the tooth replacement and wear technique and the cementum annuli technique, contact the Missouri Department of Conservation, <http://mdc.mo.gov>.

Illustrations by Charles W. Schwartz (Figures 3–6) are reprinted with permission from *The Wild Mammals of Missouri*, University of Missouri Press and Missouri Department of Conservation.

#### ALSO FROM MU EXTENSION PUBLICATIONS

- G9479 *Ecology and Management of White-tailed Deer in Missouri*
- G9480 *Implementing Quality Deer Management on Your Property*
- G9481 *Estimating Deer Populations on Your Property: Camera Survey*
- G9482 *Estimating Deer Populations on Your Property: Observational Data*
- G9483 *Estimating Deer Populations on Your Property: Harvest Data*
- G9485 *Techniques for Aging Live Deer*
- G9486 *Antler Development in White-tailed Deer: Implications for Management*
- G9487 *Nutritional Requirements of White-tailed Deer in Missouri*
- G9488 *White-tailed Deer Population Dynamics in Missouri: Implications for Management*
- G9489 *Potential Diseases and Parasites of White-tailed Deer in Missouri*
- G9490 *Managing for White-tailed Deer in Missouri: Establishing a Wildlife Management Cooperative*
- G9491 *Managing for White-tailed Deer in Missouri: Setting and Accomplishing Management Goals*

**[extension.missouri.edu](http://extension.missouri.edu) | 800-292-0969**